

# Histopatologi of liver and intestine of pangkulan bare fish

*by* Dwi Kesuma

---

|                |  |                 |       |
|----------------|--|-----------------|-------|
| FILE           | AHMI_2019_IOP_CONF._SER._EARTH_ENVIRON._SCI._370_012078.PDF<br>(619.58K) |                 |       |
| TIME SUBMITTED | 05-JUN-2020 06:08AM (UTC+0700)   | WORD COUNT      | 3458  |
| SUBMISSION ID  | 1337937447   | CHARACTER COUNT | 18290 |

PAPER • OPEN ACCESS

## Histopathology of liver and intestine of pangkulan bare fish (*Oryzias matanensis*) Polluted by nickel and iron in Lake Matano, South Sulawesi

17

To cite this article: Ummi Fahmi *et al* 2019 *IOP Conf. Ser.: Earth Environ. Sci.* **370** 012078

6

View the [article online](#) for updates and enhancements.

## Histopathology of liver and intestine of pangkulan bare fish (*Oryzias matanensis*) Polluted by nickel and iron in Lake Matano, South Sulawesi

Umami Fahmi<sup>1</sup>, Irma Andriani<sup>2</sup>, Shelly Salmah<sup>3</sup>, Triany Hastuti Hatta<sup>3</sup>, Sharifuddin Bin Andi Omar<sup>4</sup> and Dwi Kesuma Sari<sup>1\*</sup>

<sup>1</sup>Study Program of Veterinary Medicine, Faculty of Medicine, Hasanuddin University, Jl. Perintis Kemerdekaan Km.10, Makassar,90245, Indonesia

<sup>2</sup>Study Program of Biology, Faculty of Mathematics and Natural Sciences, Hasanuddin University, Jl. Perintis Kemerdekaan Km.10, Makassar,90245, Indonesia

<sup>3</sup>Department of Histology, Faculty of Medicine, Hasanuddin University, Jl. Perintis Kemerdekaan Km.10, Makassar,90245, Indonesia

<sup>4</sup>Faculty of Marine and Fisheries Science, Hasanuddin University, Jl. Perintis Kemerdekaan Km.10, Makassar,90245, Indonesia

E-mail: dwiksari@vet.unhas.ac.id

**Abstract.** Pangkulan Bare fish or Matano Medaka fish (*Oryzias matanensis*) is one of the most endemic species of freshwater fish that lives on Lake Matano. The purpose of this study was to determine the histopathology of the liver and intestines of the Matano Medaka fish contaminated by iron and nickel. The samples used were 6 fish with average size was 48.36 mm ± 0.74 mm. Samples were then processed with host technique analysis. Based on the results of this study obtained histopathological change that occurs in the liver and intestine in the form of hemorrhage, necrosis, fat degeneration, hydropic degeneration, lysis of hepatocytes and numerous melano macrophage. The results of measuring the water content of Matano lake contain iron (Fe) <0.03 mg / L and nickel (Ni) <0.07 mg / L. Therefore, the results of measurements of metal content in Matano lake sediments contain iron (Fe) 3.08% and nickel (Ni) 0.15%. The results of these measurements averaged above the threshold. Therefore, the high concentration of metals is thought to have a relationship with the abnormal tissue of fish organs observed in this study.

### 1. Introduction

Lake Matano is a lake in the South Sulawesi Province, which has a high endemic rate, which has a large variety of biota. The difference in the height of this lake with surrounding lakes is also a determinant for the migration of inter-lake organisms, especially from the downstream to the upstream, so this is a factor that causes patterns of distribution or distribution of unique organisms and endemic species [1]. Based on the research results of one of the endemic fish in Matano lake, namely *Oryzias matanensis* [2]. Matano Medak fish has 41 - 47 rows of scales along the body, a total length of 4.5 - 5.5, the tail fin is rather concave, has a special coloring pattern in male fish. The eyes are blue, dorsal, anal, tail, and black dorsal fins. Females have a lighter brown color on the head and body and large eyes. The economic



Content from this work may be used under the terms of the [Creative Commons Attribution 3.0 licence](https://creativecommons.org/licenses/by/3.0/). Any further distribution of this work must maintain attribution to the author(s) and the title of the work, journal citation and DOI.

value of fish is as ornamental fish [3]. However, the population of these fish decreases due to the presence of industrial waste [2].

Industrial waste can threaten aquatic organisms, namely heavy metals. Metal compounds can enter very quickly and easily in the body and can accumulate in the body tissues of aquatic organisms. Besides that it can also be toxic to humans if consumed. The process of metal accumulation in tissues occurs after absorption of metals from water or through contaminated feed. Metals are absorbed by the blood, binding to blood proteins which are then distributed throughout the body's tissues. The liver is a very important organ in the body's metabolic system because it is capable of being an indicator when pathological disturbances occur mainly pathological disorders caused by heavy metals contained in aquatic ecosystems, the highest accumulation is found in detoxification (liver) [4]. While the intestine is a part of the digestive tract which functions to absorb the extracts of food so that interference with these organs can be fatal for fish growth. Although it is rarely encountered a disorder that results in death but some fish diseases have a negative impact on the overall value of production [5]. Therefore, knowledge of abnormal conditions of the intestinal organs is very important for the management of the health of the fish itself

Extinction or decline in population caused by several causative factors can be known through the histopathology of the organs that function in metabolism and the survival of an individual. Through that we can find out if there is a disease or abnormality in the individual's body, from histopathological picture it can be seen clearly the damage that occurs in the body is then linked to environmental conditions that can be a determinant or cause so that the state of pathology can occur with the existence of this research is expected to be able to provide information about the organ of microscopic bare fish which until now does not yet exist.

## 2. Materials and methods

This study used six Matano Medaka fish with size average of 4.5 cm. The fish is taken by local fishermen by directly capturing it using a net, and then stored in a container filled with water from Matano Lake. The samples fixated in 10% formalin for 2x24. Then the body length was measured using a caliper. Furthermore, the dorsal portion is removed from the end of the head and carefully opened the abdominal area. Observations were made on the liver and intestines in the abdominal area. Then the histopathological preparation process was carried out and microscopic observations were carried out with 10x subjective lens magnification and 10x and 40x objective lenses. Observation and shooting is done using a light microscope that is integrated with the camera. Histological preparations of the liver and fish intestines of *Oryzias matanensis* were then observed. The first observed part is the liver by looking at hepatocyte, sinusoidal, pancreatic cells found in the liver parenchyma, and pathological changes that occur. In the intestine body that will be observed are the intestinal lamella and pathological features of the constituent parts of the organ. Data analysis used is descriptive qualitative data analysis. In this method, it will explain the histopathology picture of the liver and fish intestine of *Oryzias matanensis*.

## 3. Results and discussions

Water and sediment test results (table 1, 2) indicate the presence of water pollution in the area including nickel and iron. Pollution occurs due to several factors including waste from a factory near the lake. This study showed that the lake contains as much as <0.07 mg / L nickel, iron as much as <0.03 mg / L for iron the maximum limit has been set in the regulation of the Governor of South Sulawesi Number 69 of 2010 which is a quality requirement of 0.3 mg / L while nickel the maximum limit is set at Regulation of the Minister of Health of the Republic of Indonesia Number 70 of 2016 with the maximum permissible level of 0.07 mg / L. Parameters of heavy metal content according to Indonesian National Standard (SNI) based on Minister of Environment of the Republic of Indonesia Regulation Number 5 of 2014 concerning Waste Water Quality Standards state that iron is allowed as much as 5 mg / L and Nickel as much as 0.02 mg / L. So that the iron content of Matano Lake water is based on the regulation of the Governor of South Sulawesi Number 69 of 2010, which reaches the maximum allowable limit. While

the nickel content in Matano Lake water based on SNI standards based on the Republic of Indonesia's Minister of Environment Regulation No. 5 of 2014 concerning Waste Water Quality Standards, has exceeded the permissible threshold.

**Table 1.** Results of Lake Matano water tests on metal content

| Parameter   | Unit | Results | Quality requirements #) |    | Test method      |
|-------------|------|---------|-------------------------|----|------------------|
|             |      |         | I                       | II |                  |
| Iron (Fe)   | mg/L | <0.03   | 0.3                     | -  | SNI 6989.4: 2009 |
| Nickel (Ni) | mg/L | <0.07   | -                       | -  | SNI 6989.18:2009 |

\*) REGULATION OF THE GOVERNOR OF SOUTH SULAWESI NO.69 of 2010 Concerning Quality Standards and Criteria for Environmental Damage, Lamp. No. I. A. Criteria for Environmental Damage Based on Class.

The test results of the sediment metal content of Ni and Fe in D. Matano waters, obtained results of Fe 3.08% and Ni 0.15% in the South Sulawesi Governor Regulation No. 69 of 2010 concerning Quality Standards and Environmental Damage Criteria, Appendix IA concerning Water Quality Standards Sea and Sea Sediments Ni and Fe standard levels in sediments are not listed.

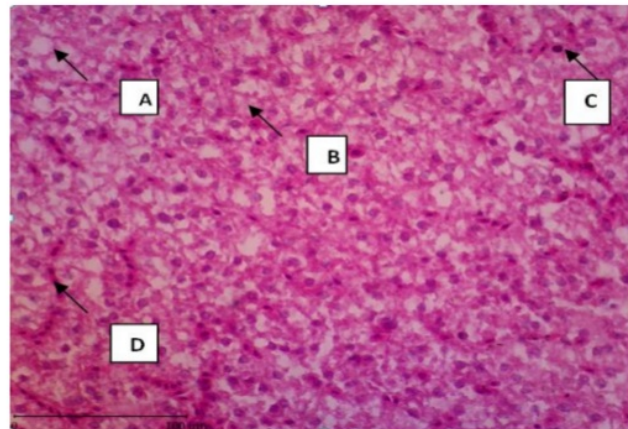
**Table 2.** Test results of sediment metal content in the waters of Lake Matano.

| Parameter  | Unit | Results | Test method |
|------------|------|---------|-------------|
| Besi (Fe)  | %    | 3.08    | AAS         |
| Nikel (Ni) | %    | 0.15    | AAS         |

\*) REGULATION OF THE GOVERNOR OF SOUTH SULAWESI NO.69 of 2010 Concerning Quality Standards and Criteria for Environmental Damage, Lamp. No. I. A. Criteria for Environmental Damage Based on Class.

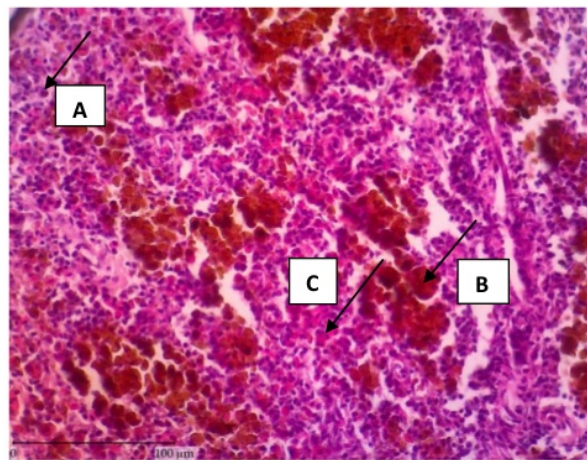
Then it can be concluded that the presence of Fe and Ni in sediments in waters is not permitted because these two heavy metals are not allowed to exist in water and cause toxicity to waters.

The results showed the existence of fat degenerati<sup>3</sup> and hydropic degeneration. Degeneration is an early sign of damage due to toxins that are temporary and the cell can still recover or return to normal if the toxin exposure is stopped. Hydropic degeneration is a condition where the cytoplasm of cells contains water due to damage to cell membranes. According to [6], the entry of water into the cytoplasm results from damage to the cell membrane and a decrease in oxidative phosphorylation, resulting in a decrease in ATP supply which causes a decrease in Na pump work.



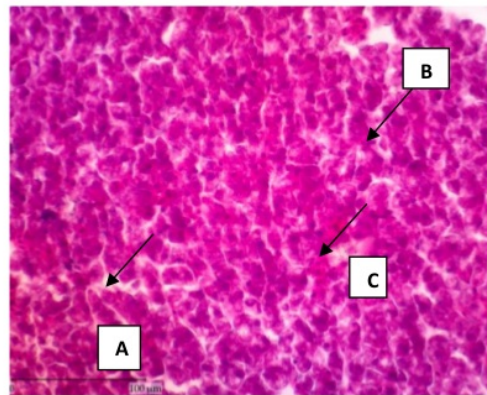**Figure 1.** Microscopic description of fish liver 1 lake Matano. (A) Hemorrhage, (B) Necrosis, (C) Fat Degeneration, (D) Hydropic Degeneration, HE, scale line: 100 microns.

Microscopically in cells that experience hydropic degeneration, there are clear spaces in the cytoplasm but not as clear as fat degeneration [7]. Small vacuoles can unite to form larger vacuoles so that the cell nucleus is pushed to the edge. Hydropic degeneration is generally caused by metabolic disorders such as hypoxia due to the influence of toxic compounds, especially iron that enters the body [8]. Fat degeneration also occurs which is marked by the accumulation of fat inside the cell. According to [7], fat accumulation occurs due to decreased cellular enzyme activity resulting in the inability of non-adipose tissue to metabolize a number of lipids. This fat degeneration occurs in marine animals due to excessive toxic amounts, especially the accumulation of nickel-metal which decreases cellular enzyme activity, resulting in the formation of fat accumulation [6].



**Figure 2.** Microscopic depiction of fish liver 2 of Lake Matano. (A) Necrosis, (B) Melanomakrophage, (C) Hemorrhage. HE, scale line: 100 microns.

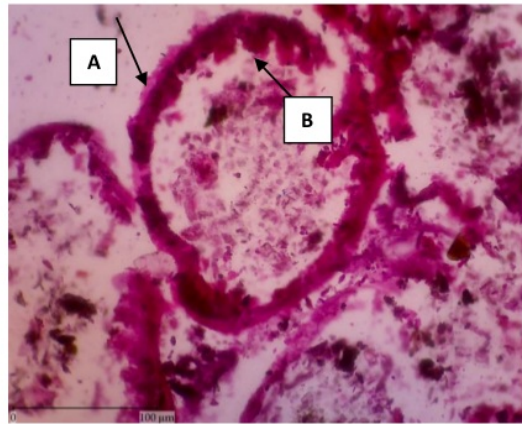
Melanomakrophage can be interpreted as a solid round cell that has a varying amount of pigment, found in healthy fish but the number increases in cases of chronic stress. The results showed excessive Melanomakrophage because 54% of the images showed excessive macrophages. Melanomakrophage is an indicator of chronic stress although it is not always persistent [9]. According to [10], melano macrophage is a collection of macrophages that contain hemosiderin, lipofuscin, and seroids as well as the melanin pigment found in most lymphoid tissues caused by inflammation of most teleost. Melanomakrophage will increase in number in pathological conditions. The denser the population the higher the number of melanomakrophage. It is estimated that the large number of melanomakrophage is caused by the dense population of fish in D. Matano.



**Figure 3.** Microscopic depiction of 3 Matano lake fish liver. (A) Sinusoid Dilatation, (B). Necrosis, (C) Hemorrhage. HE, scale line: 100 microns.

Based on the results of the study showed sinusoid dilatation. The sinusoid is a tortuous blood vessel that is coated with intact, endothelial cells, which are separated from the hepatocytes beneath it by the perisinusoidal space. Sinusoid dilatation results in food substances flowing in the sinusoids, penetrating endothelial walls that are not intact and in direct contact with hepatocytes. Sinusoid dilatation can occur due to pressure on the sinusoid wall due to the presence of toxic substances, especially lead and nickel [11].

The results of the liver picture show the presence of hemorrhage. Hemorrhage or bleeding is characterized by the presence of blood spots in blood vessels. This is in accordance with a research by [12] which states that the toxic exposure, especially iron at a magnification of 40x10 shows the occurrence of hemorrhage, due to the increasing toxic substances that are physiologically present in the tissue. Necrosis also occurs, which is marked by the occurrence of liver cell death. Necrosis begins with a liver inflammation reaction in the form of swelling of hepatocytes and tissue death. Necrosis is an advanced stage of degeneration because too much material has to be reabsorbed by hepatocyte cells, causing cell death to occur along with the rupture of the plasma membrane. This is caused if fat is deposited in large amounts resulting in the death of liver cells. Based on the results of [13] which reported that the liver of Tilapia which underwent pathological changes in the form of cell fat and necrosis was the result of the liver having accumulated with heavy metals (Fe, Cu, Zn, Mn, Pb and Cd) as well as in [14] states that the liver of Butini fish experiences fat degeneration, hydropic degeneration, cell hypertrophy and hepatocyte cells that have necrosis caused by the presence of heavy metals iron and nickel in D.Matano. The level of liver damage is categorized into three, mild levels of fatty liver which is characterized by cell swelling. In this study, the damage to the liver tissue of Bangkilan Bare fish including the degree of damage to severe damage.



**Figure 4.** A. Intestine with unclear (external) and circular (internal) longitudinal muscle boundaries. B. Damage to the intestinal villi. HE, scale line: 100 microns.

Based on the results obtained on the intestine image, there is an unclear appearance of longitudinal and circular muscle boundaries. Intestinal muscularis consists of circular (internal) smooth muscle and longitudinal (external) smooth muscle. In the narrowing between the pars of the pylorus and the front intestines of the bare breeches found thin longitudinal (internal) smooth muscle and thick circular (external), have the function of spherical muscles that work autonomously. The thickness of the tunica muscularis of fish intestines is different, the thickest of the middle intestine and the thinnest of the intestine. Musculoskeletal tunica in the middle intestine can function to hold food from going quickly to other parts of the intestine, so that food can take longer to undergo digestion and absorption processes in the front intestine [15]. The unclear upper boundary between the circular authority and the longitudinal muscles in the intestine shows that the muscles that hold food so as not to run quickly to the other intestines have been damaged so that the digestive process is not going well. The damage that occurs next is in the intestinal villi is not very clear and has very severe damage, this causes disruption in the process of absorption of nutrients, causing disruption of the process of growth and reproduction even causing death. The damage was thought to be a result of heavy metal exposure to bare fish (*Oryzias matanensis*). This assumption is reinforced by [6] which states that damage to the intestine is caused by exposure to foreign objects including excessive toxic in the body after research by [16] found damage to the intestinal epithelium and the removal of intestinal villi and basal lamina in the intestines of Dui fish -Dui contaminated with heavy metal nickel and iron in Lake Matano. In chronic conditions this can cause hyperplasia of goblet cells whose numbers will increase dramatically. Goblet cells will experience an increase aimed at sustaining life from toxic exposure. Goblet cells synthesize and secrete high molecular weight glycoproteins called mucin. Mucus production can increase mucosal surface protection against foreign body exposure.

As for this research, it was obtained damage or histopathology that occurs in the liver in the form of hemorrhage, necrosis, fat degeneration, hydropic degeneration, hepatocyte cells that are lysed and melano macrophage. Whereas the intestine has no clear boundary between circular and longitudinal muscles and damage to the intestinal villi. From the results of measurements of metals in the lake containing nickel which on average approaches the maximum limit. Damages that occur are thought to be caused by exposure to heavy metals dissolved in the waters of the fish ecosystem which have passed the threshold.

#### Acknowledgment

The author would like to thank the managers of the Pathology Laboratory, Study Program of Veterinary Medicine, Faculty of Medicine, Hasanuddin University. In addition, the authors also thank the fishermen

who helped in this research. The author states there is no conflict of interest with the parties concerned in this study.

## References

- [1] Nontji A 2016 *Danau Danau Alami Nusantara* (Jakarta: Pusat Penelitian Oseanografi Lembaga Ilmu Pengetahuan Indonesia) <sup>15</sup>
- [2] Hadiaty R and Wirjoatmojo S 2002 Studi Pendahuluan biodiversitas dan distribusi ikan di Danau Matano, Sulawesi Selatan *J. Iktiologi Indones.* **2** 23–9 <sup>8</sup>
- [3] Haryo 2006 Tinjauan Habitat Ikan Air Tawar Langka dan Terancam Puna di Indonesia (Bogor: Pusat Penelitian Biologi Lembaga Ilmu Pengetahuan Indonesia) <sup>5</sup>
- [4] Palar H 1994 *Pencemaran dan Toksikologi Logam Berat* (Jakarta: Rineka Cipta)
- [5] Susanto D 2008 *Gambaran Histopatologi Organ Insang, Otot, dan Usus Ikan Mas (Cyprinus Carpio) di Desa Cibanteng* (Institut Pertanian Bogor)
- [6] Underwood J C E 1999 *General and Systematic Pathology* (New York: Churchill Livingstone)
- [7] Carlton W W and Gavin M D 1995 *Special Veterinary Pathology 2nd Edition* (Missouri: Morsby-Year Book, Inc) <sup>10</sup>
- [8] Rusmiati L A 2004 Struktur histologis organ hepar dan ren menci (Mus musculus) jantan setelah perlakuan dengan ekstrak kayu secang (Caesalpinia sappan L). *Bioscientiae* **1** 23–30
- [9] Noga E J 2010 *Fish Disease : Diagnosis and Treatment. 2nd ed.* (Iowa: Wiley Blackwell)
- [10] Natalia C . and I.B. D 2017 Melanomacrophage Centers As a Histological Indicator of Immune Function in Fish and Other Poikilotherms *Front Immunol.* **8** 1–8
- [11] Novi E 2015 *Pengaruh Ekstrak Daun Sirsak (Annona Muricata L.) Terhadap SOD dan Histologi Hepar Tikus (Rattus norvegicus) yang Diinduksi Aloksan* (Universitas Islam Negeri Maulana Malik Ibrahim)
- [12] Tridayani A E, Riris A and Gusti D 2010 Pengaruh logam timbal (pb) terhadap jaringan hati ikan kerapu bebek (Cromileptes altivelis) *Maspari J.* **1** 42–7 <sup>4</sup>
- [13] El-Naggar A M, Mahmoud S A and Tayel S I 2009 Bioaccumulation of some Heavy Metals and Histopathological Alterations in Liver of Oreochromis niloticus in Relation to Water Quality at Different Localities along the River Nile, Egypt *World J. Fish Mar. Sci.* **2** 105–14
- [14] Andini N S 2015 *Gambaran Histopatologi Insang, Hepatopankreas dan Usus Ikan Butini (Glossogobius matanensis, weber) di Danau Matano Luwu Timur Sulawesi Selatan yang Tercemar Logam Berat Nikel (Ni) dan Besi (Fe)* (Universitas Hasanuddin) <sup>7</sup>
- [15] Yusfiat P, Sigit K, Affandi R and Nurhidayat 2006 Anatomi alat pencernaan ikan buntal pisang (Tetraodon lunaris) *J. iktiologi* **6**
- [16] Asri A 2015 *Gambaran Histopatologi Usus Ikan Dui Dui (Dermogenys megarrhamphus) di Danau Matano Luwu Timur Sulawesi Selatan yang Tercemar Logam Berat Nikel (Ni) dan Besi (Fe)*. (Universitas Hasanuddin) <sup>14</sup>

# Histopatologi of liver and intestine of pangkulan bare fish

## ORIGINALITY REPORT

%**9**

SIMILARITY INDEX

%**5**

INTERNET SOURCES

%**3**

PUBLICATIONS

%**5**

STUDENT PAPERS

## PRIMARY SOURCES

**1**

**Submitted to Universitas Dian Nuswantoro**

Student Paper

%**2**

**2**

**earchive.tpu.ru**

Internet Source

%**1**

**3**

**Nia Rossiana, Kartiawati Alipin, Desak Malini, Ida Indrawati, Sri Rejeki Rahayuningsih, Nana Media, Yayat Dhahiyat. "Urgency longterm oil sludge biophytoremediation: Acute, subchronic toxicity on liver and kidney rats", Environmental Technology & Innovation, 2020**

Publication

%**1**

**4**

**Submitted to Universitas Airlangga**

Student Paper

%**1**

**5**

**es.scribd.com**

Internet Source

<%**1**

**6**

**iopscience.iop.org**

Internet Source

<%**1**

**7**

**digilib.uin-suka.ac.id**

Internet Source

<%**1**

|    |  |      |
|----|--|------|
| 8  | <a href="http://jppik.id">jppik.id</a><br>Internet Source  | <% 1 |
| 9  | Submitted to Charles Sturt University<br>Student Paper   | <% 1 |
| 10 | Submitted to Tikrit University<br>Student Paper  | <% 1 |
| 11 | <a href="http://arizona.openrepository.com">arizona.openrepository.com</a><br>Internet Source  | <% 1 |
| 12 | <a href="http://china.iopscience.iop.org">china.iopscience.iop.org</a><br>Internet Source  | <% 1 |
| 13 | <a href="http://worldwidescience.org">worldwidescience.org</a><br>Internet Source  | <% 1 |
| 14 | Safran Makmur, Husnah Husnah, Samuel Samuel. "IKAN DUI DUI (Dermogenys megarrhamphus) IKAN ENDEMIK DI DANAU TOWUTI SULAWESI SELATAN", BAWAL Widya Riset Perikanan Tangkap, 2017<br>Publication | <% 1 |
| 15 | <a href="http://jurnal.unmuhjember.ac.id">jurnal.unmuhjember.ac.id</a><br>Internet Source  | <% 1 |
| 16 | Submitted to The University of the South Pacific<br>Student Paper  | <% 1 |
| 17 | Submitted to Universitas Hasanuddin<br>Student Paper   | <% 1 |

18

[eprints.unm.ac.id](http://eprints.unm.ac.id)

Internet Source

<% 1

---

19

[reviewboard.ca](http://reviewboard.ca)

Internet Source

<% 1

---

EXCLUDE QUOTES ON

EXCLUDE ON

BIBLIOGRAPHY

EXCLUDE MATCHES < 5

WORDS